



## RHINOPLASTY: BASIC APPROACHES AND TECHNIQUES IN NASAL TIP SURGERY

GJ Nolst Trenité

The variety of procedures for nasal tip surgery and the individual differences in tip anatomy are complicated by the confusing terminology in the international literature. It was Tardy who advocated a systematic rational approach to the nasal tip. With this framework in mind, the inexperienced nasal surgeon can use the appropriate incisions, approaches and techniques more easily. The basic philosophy is to operate as atraumatically as possible and to preserve tip support, which is very important in getting good long term postoperative results.

There are *three basic surgical approaches* to the tip of the nose:

1. Non-delivery approach
  - Cartilage-splitting
  - Retrograde eversion
2. Delivery approach
3. External approach

Indications for each of these approaches depend on the specific anatomy of the nose and the proposed changes:

- Volume reduction
- Reconstruction
- Rotation
- Change of projection

### Surgical Procedures

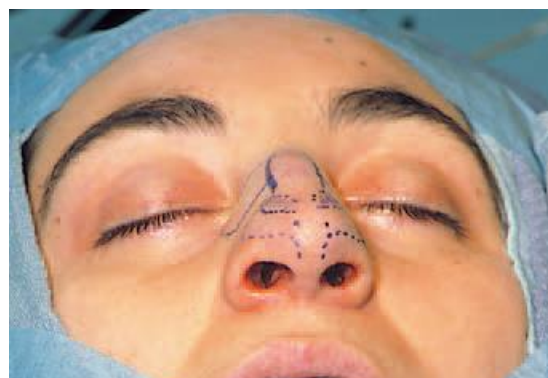#### 1. *Non-delivery approach*

The non-delivery approach is very appropriate for:

- Small volume reduction of the lateral crus
- Slight cephalic rotation of the tip

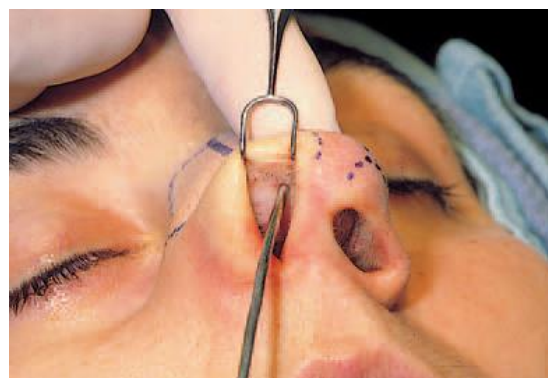
Volume reduction can easily be done using a transcartilaginous incision, in which only slight surgical trauma occurs.

The operative procedure for the *cartilage splitting non-delivery approach* is as follows: after drawing the skeletal landmarks and boundaries on the skin of the nose, the most cephalic part of the lateral crus to be resected is outlined with a marking pen on the external skin (*Figure 1*).

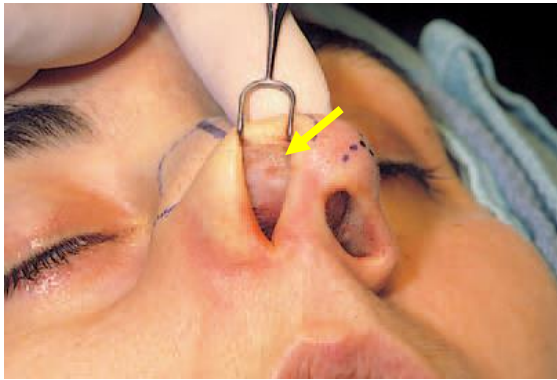


*Figure 1: Drawing of the skeletal landmarks and the planned resection on the skin*

It is helpful to indicate on the vestibular skin where the transcartilaginous incision should be made. This can be done either by a through-and-through needle from the outside or, more elegantly, by using the imprint of a surgical instrument on the vestibular skin (*Figures 2a,b*).



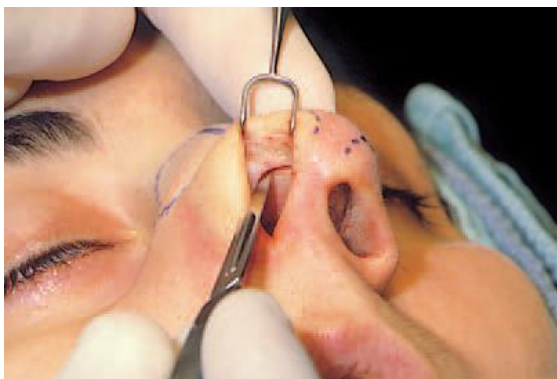*Figure 2a: Imprint of the vestibular skin with a suction tube to mark the planned site of the transcartilaginous incision*



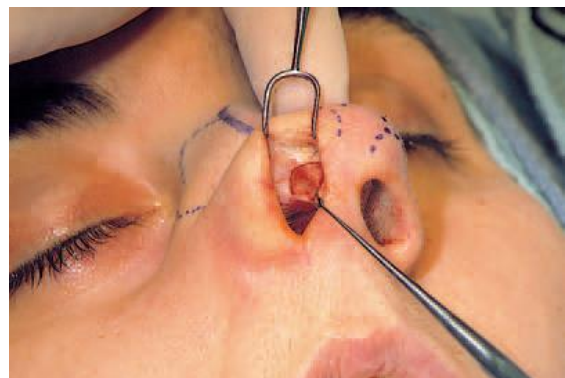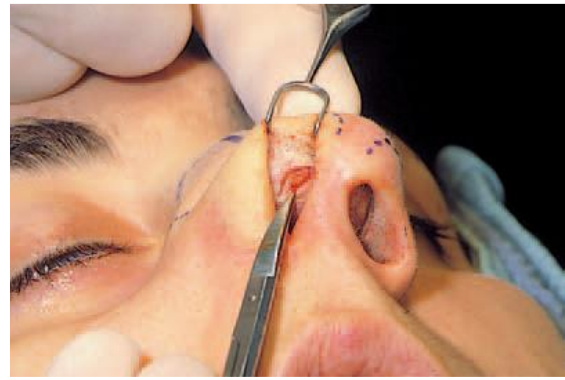*Figure 2b: Suction tube imprint of the vestibular skin (arrow)*

Care should be taken to preserve at least 5mm of uninterrupted cartilage (in a vertical dimension) of the lateral crus.

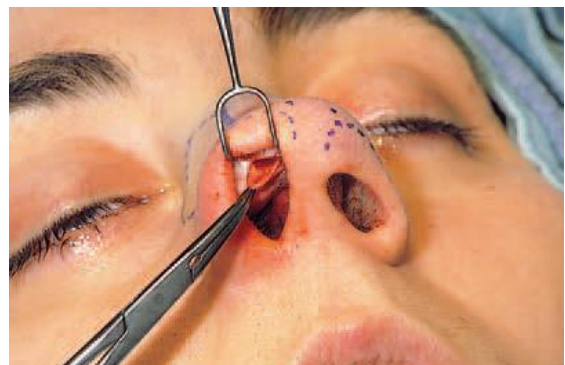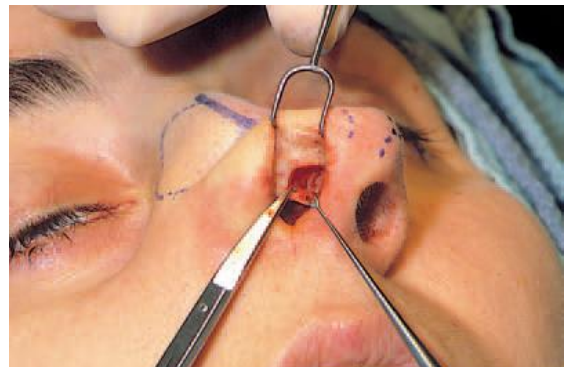Although many surgeons make their incisions through the vestibular skin and cartilage at once, it facilitates the dissection of the vestibular skin to do this in two stages. A vestibular skin incision with a No. 15 blade (*Figure 3*) is followed by dissecting the vestibular skin free from the proposed resection of the cephalic part of the lower lateral cartilage with a pair of sharp pointed curved scissors (*Figures 4a,b*). After splitting the cartilage (No. 15 blade), the non-vestibular side of the cephalic part to be resected is dissected free from the overlying soft tissue and removed (*Figures 5a-d*). Pressure of the middle finger of the operator's hand (holding the double-hooked ala retractor) on the lateral crus will give excellent exposure and control during surgery.



*Figure 3: Vestibular skin incision*

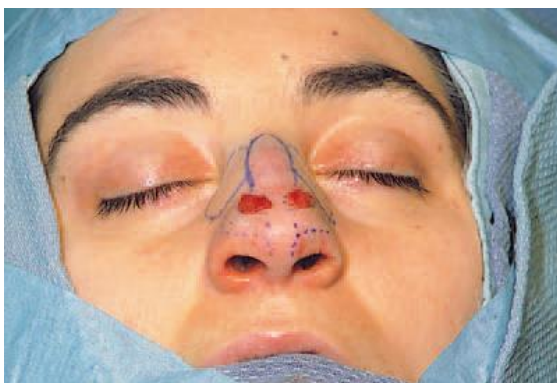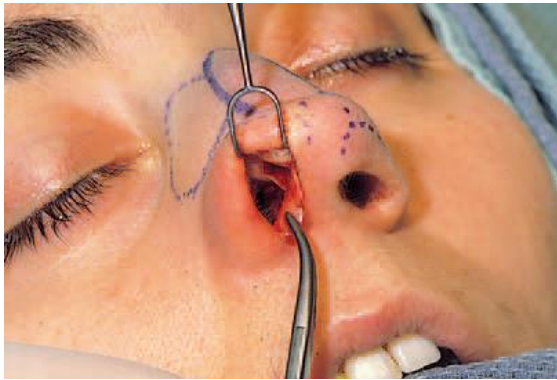


*Figures. 4a,b: The vestibular skin is dissected free from the cephalic part of the lateral crus to be resected*



*Figure 5a,b. Dissection at the nonvestibular site after splitting the cartilage*





Figures 5c,d: Resection of cephalic parts of the lateral crura

After sufficient and symmetric volume reduction, the vestibular skin should be sutured carefully with 5/0 atraumatic absorbable suture material. This simple tip refinement procedure gives minimal surgical trauma, leaving the integrity of the lower lateral intact ensuring the best chances for uncomplicated healing process.

Nowadays, the **retrograde-eversion approach** is performed less often. Instead of a transcartilaginous incision, an **intercartilaginous incision** is made followed by retrograde dissection over the lateral crus at the non-vestibular side, eversion of the lateral crus and resection of the planned cephalic portion of the cartilage.

## 2. Delivery approach

The **delivery approach**, although more traumatic, is indicated when the planned changes to the nasal tip are more than just a small volume reduction.

The indications for this approach are:

- Asymmetry
- Bifidity
- Extra cephalic tip rotation
- Diminishing of the tip projection

With this approach, it is possible to modify the alar cartilages under direct vision up to the dome and interdomal area. Different operative techniques can be applied:

- Precise excision of cartilage to achieve good symmetry
- Remodelling the alar cartilages by scoring and morselization
- Interdomal suturing to correct bifidity
- Interruption of the continuity of the alar cartilage to reduce an extremely over-projected tip ('pinocchio' nose) or to enhance cephalic tip rotation.

The surgical procedure to deliver the alar cartilages starts with an intercartilaginous incision with a No. 15 blade. It is important to make this incision caudally to the valve area to prevent unnecessary scarring in the valve area. This intercartilaginous incision should be carried well around the anterior septal angle (Figure 6). If not, delivery could be stagnated.

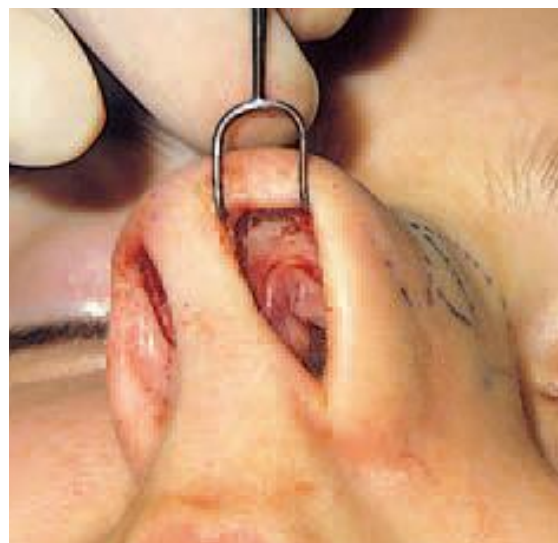

Figure 6: Intercartilaginous incision caudal to the valve area and around the anterior septal angle

The next step is to make a marginal incision (No. 15 blade), hugging the caudal edge of the lower lateral to prevent surgical damage to 'the soft triangle'. The incision starts at the upper part of the caudal edge of the medial crus, then goes around the dome and follows the caudal edge of the lateral crus as far as necessary (Figure 7).

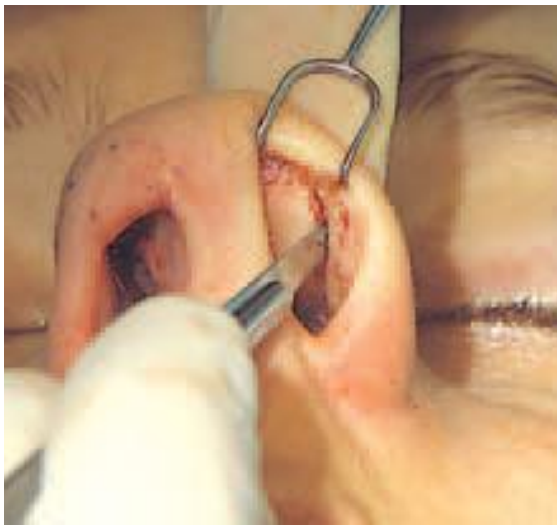
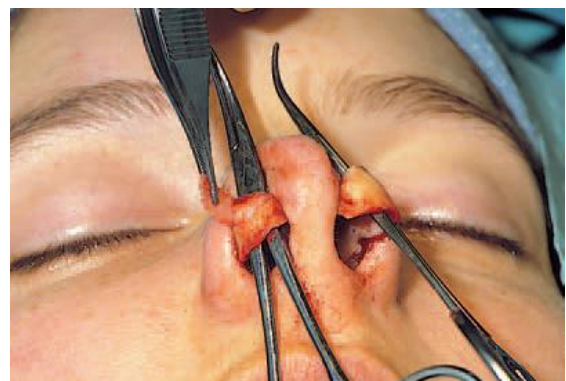
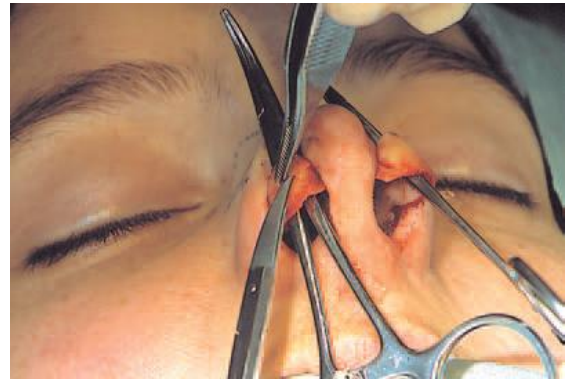Figure 7: Marginal incision

After these two incisions, the non-vestibular side of the lateral crus is freed from the soft tissue by dissection with a pair of sharp pointed curved scissors. To deliver the bipediced chondrocutaneous flaps, small haemostats are very handy. Precise excision of cartilage is now possible under direct vision (Figures 8a,b).

In the case of bulging of the lateral crus, the weakening procedure (scoring or morselization) is performed, if indicated in combination with resection of a cephalic portion of the lateral crus (Figures 9a,b).



Figures 8a,b: Precise dissection and excision of a cephalic portion of the lateral crus

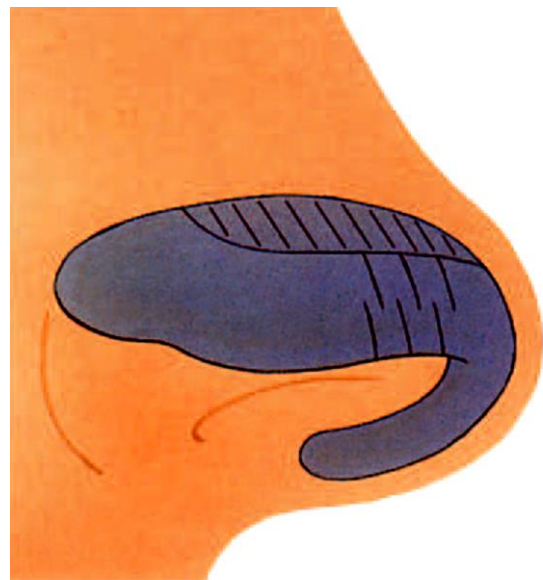
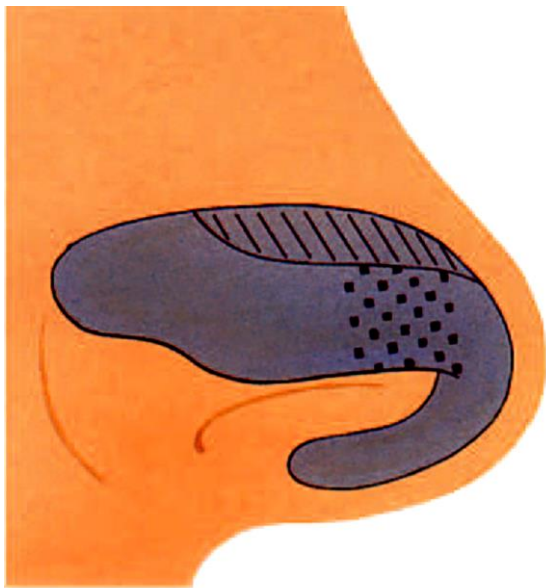
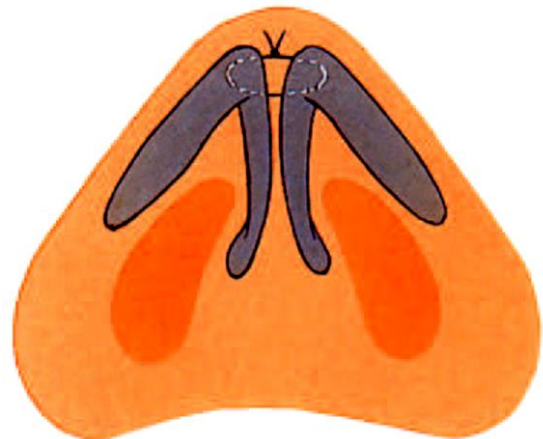
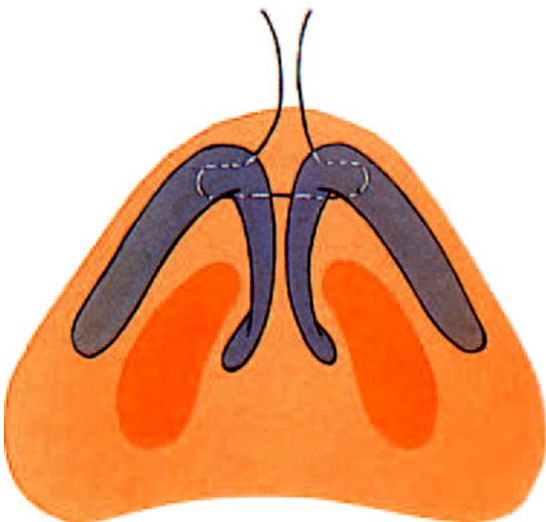


Figure 9a: Weakening procedure of the lateral crus by scoring the cartilage

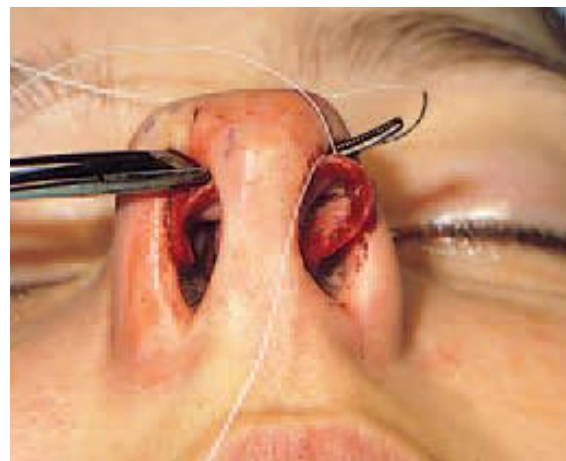
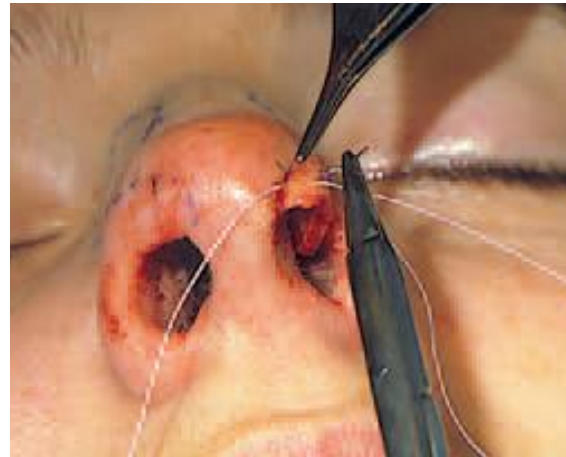


*Figure 9b: Weakening procedure of the lateral crus by morselization*

The delivery approach is also appropriate in the case of bifidity of the nasal tip, in which the horizontal mattress suture technique can be performed to advance the domes with a non-absorbable (Goretex) or a slow absorbable (PDS) atraumatic suture (*Figures 10a-e*).

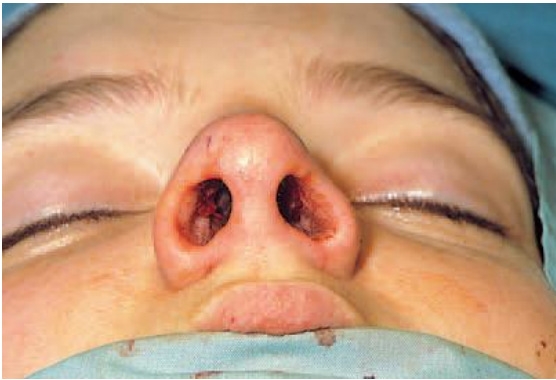

*Figures 10 a, b: Horizontal mattress suture technique to correct bifidity of the tip*



*Figures 10 c,d: Mattress suture with 6/0 Goretex of left lower lateral followed by transportation of the needle with a mosquito clamp to the right side for the same procedure*





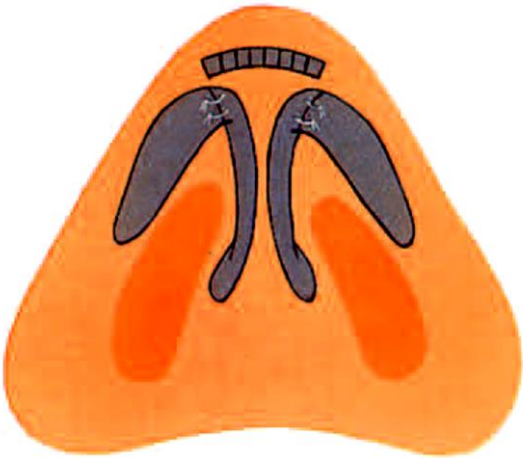*Figure 10e: Direct postoperative result after advancing the domes with horizontal mattress suture technique*

Interrupting the continuity of the alar cartilage can give some unpredictable scarring, especially visible in thin-skinned noses. In the case of dome amputation to reduce a ‘pinocchio’ nose, an onlay tip graft will hide possible irregularities in the healing process (Figures 11a,b).

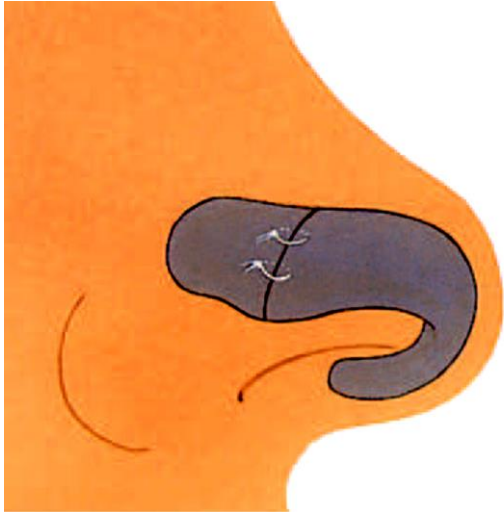
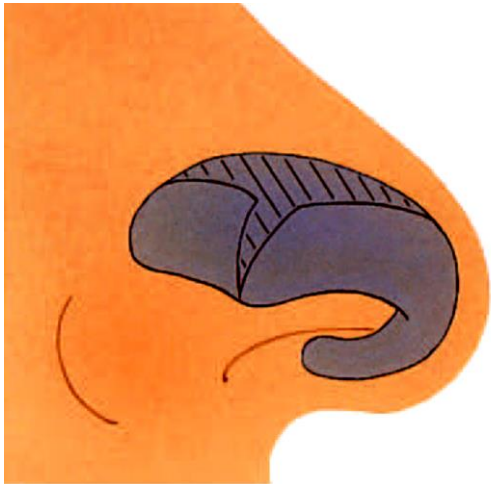
To reduce tip projection and to obtain sufficient cephalic tip rotation, as is indicated in correcting a tension nose, the continuity of the alar cartilage is interrupted by transection of the lateral crus at the junction of its middle and lateral third, followed by resection of the cartilage segment of the lateral third and cephalic part (Figures 12a,b).



*Figure 11a: Dome amputation*



*Figure 11b: Sutured lower laterals with an onlay tip graft to hide possible post-operative irregularities*



*Figures 12a,b: Interrupted strip technique to obtain adequate cephalic tip rotation in case of a tension nose*

A supplementary procedure to enhance tip rotation is resection of a caudal strip of cartilage in the septum. The surgeon should be aware that the healing process is less predictable, with more chance of postoperative asymmetries, with the delivery approach than with the non-delivery approach.

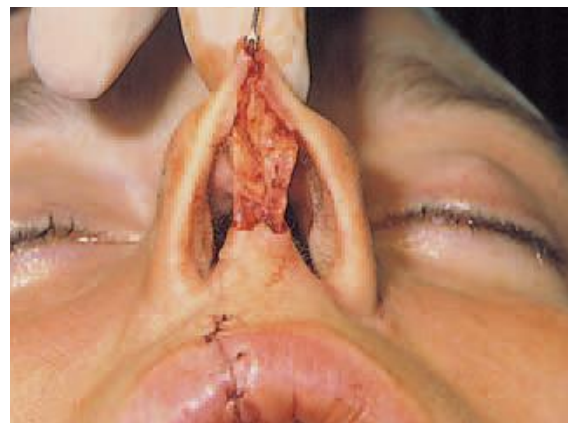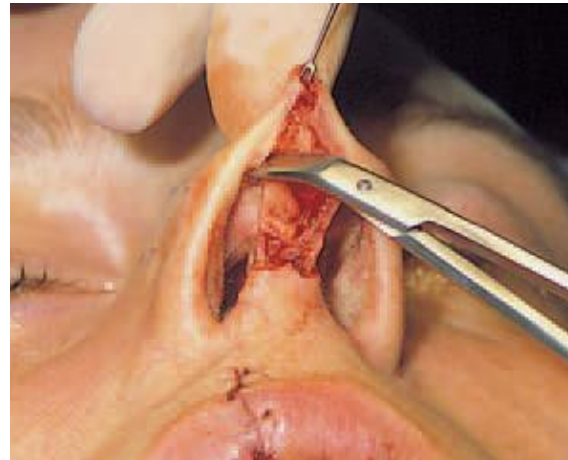### 3. *External approach*

The external approach, although even more traumatic and time consuming, gives the best exposure of the three approaches. This approach enables the surgeon to perform bimanual surgery, and it makes judgement of the specific deformities much easier. Therefore, it is especially indicated in the case of:

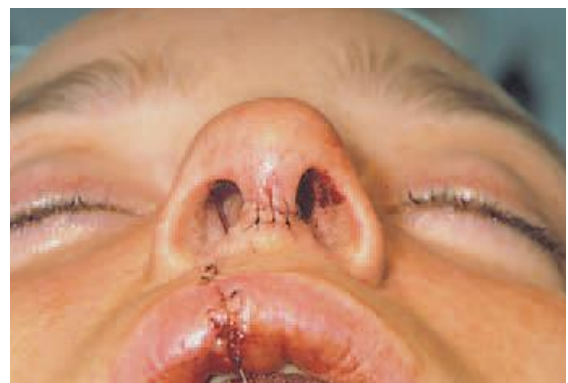- Congenital deformities such as cleft, lip nose
- Extensive revision surgery
- Severe nasal trauma
- Elaborate reduction and augmentation procedures

Nevertheless, there is a tendency to use the external approach routinely, especially by less experienced nasal surgeons. This is justified as long as the surgeon weighs the surgical trauma of the chosen approach against the possibilities of a satisfying postoperative result in each individual case.

Careful preparation of the columella skin flap (*Figures 13a,b*), without disturbing the underlying cartilage of the medial crura, and meticulous suturing of the midcolumellar skin incision (*Figure 14*), to prevent skin necrosis and visible scarring, are prerequisites.



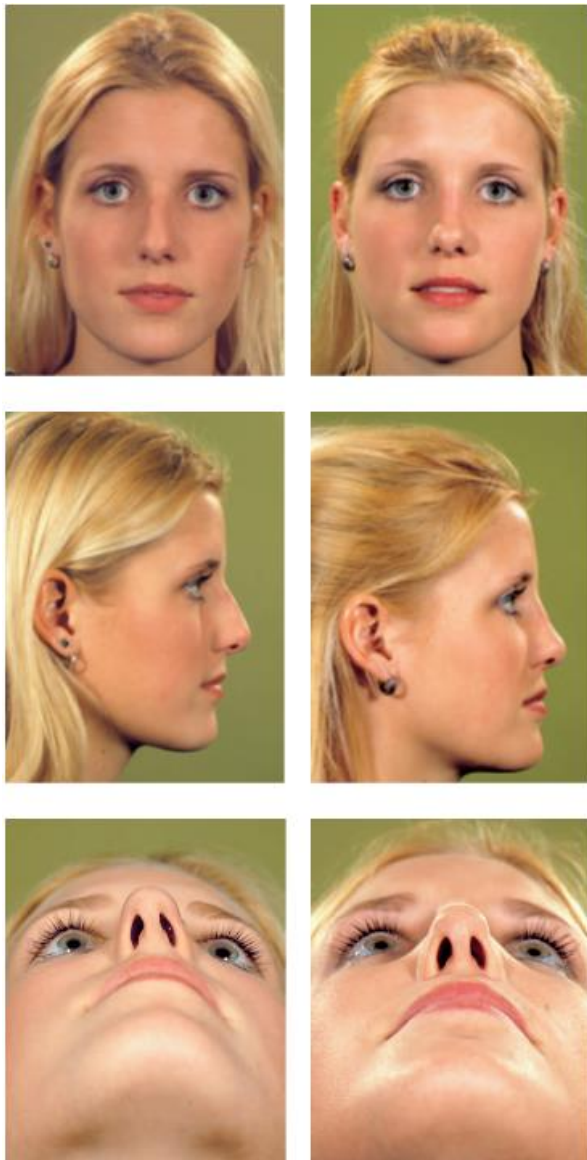*Figures 13a,b: External approach after careful preparation of the columella skin flap avoiding injury to the underlying cartilage of the medial crura*



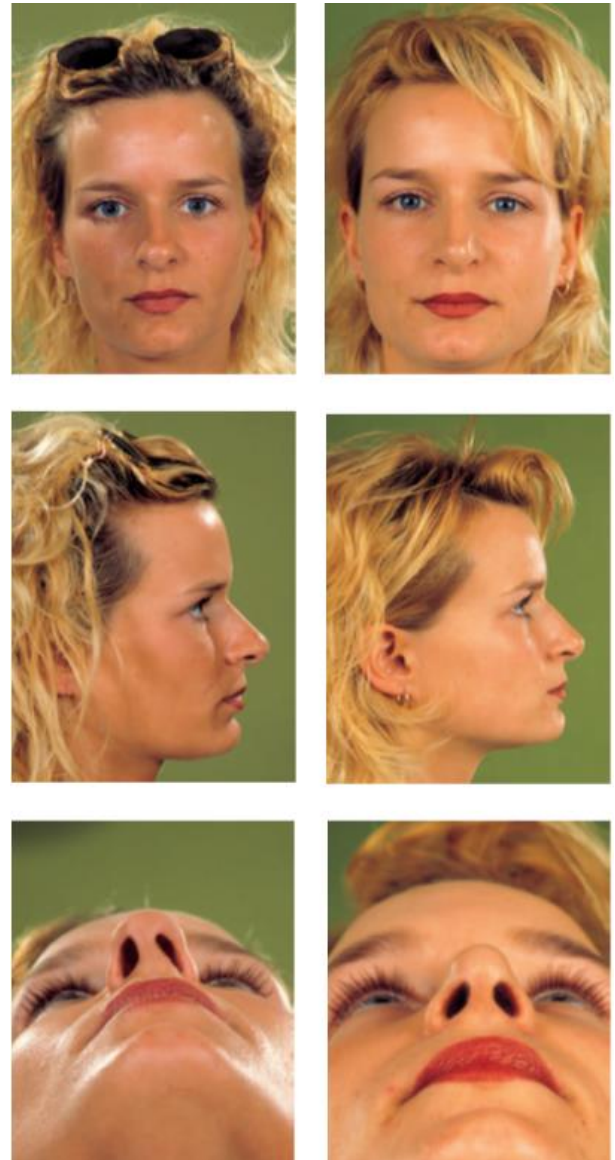*Figure 14: Meticulous suturing of the midcolumellar incision with 6/0 nylon*

### **Clinical examples**

In *Figures 15-18* clinical cases of non-delivery, delivery and external approaches are shown.

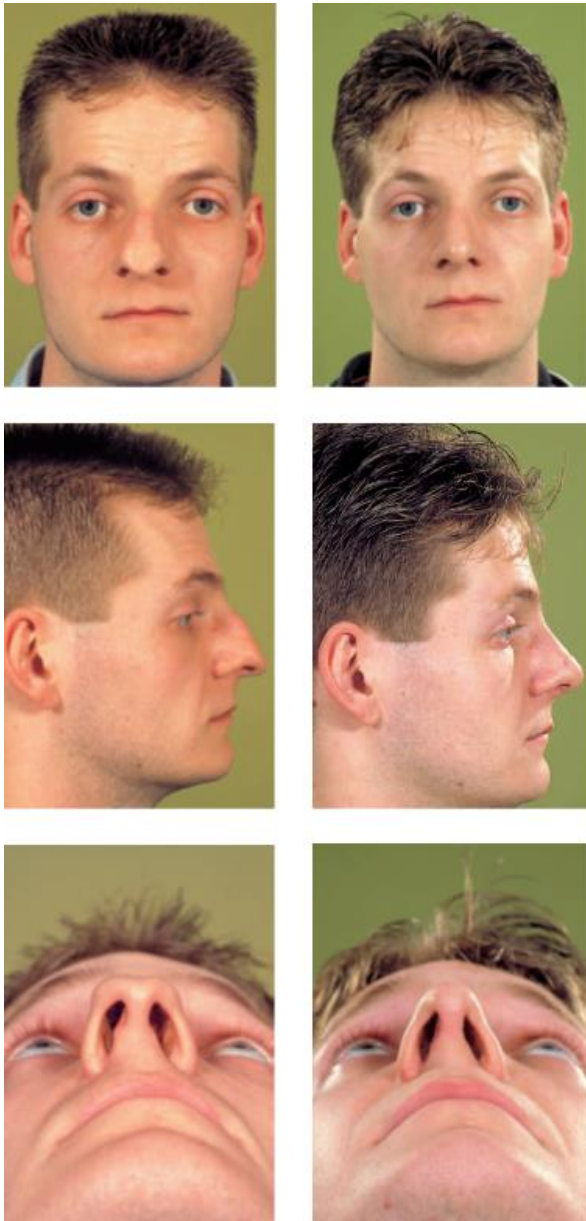


*Figure 15: Pre- (left) and postoperative (right) views of a patient who underwent a rhinoplasty by the **non-delivery approach**. First a septoplasty was performed to correct a caudal septal deviation to the left followed by a cephalic resection of the lower laterals. Then a cartilaginous bony hump was removed followed by medial oblique, lateral micro-osteotomies and infracture of the nasal bones*

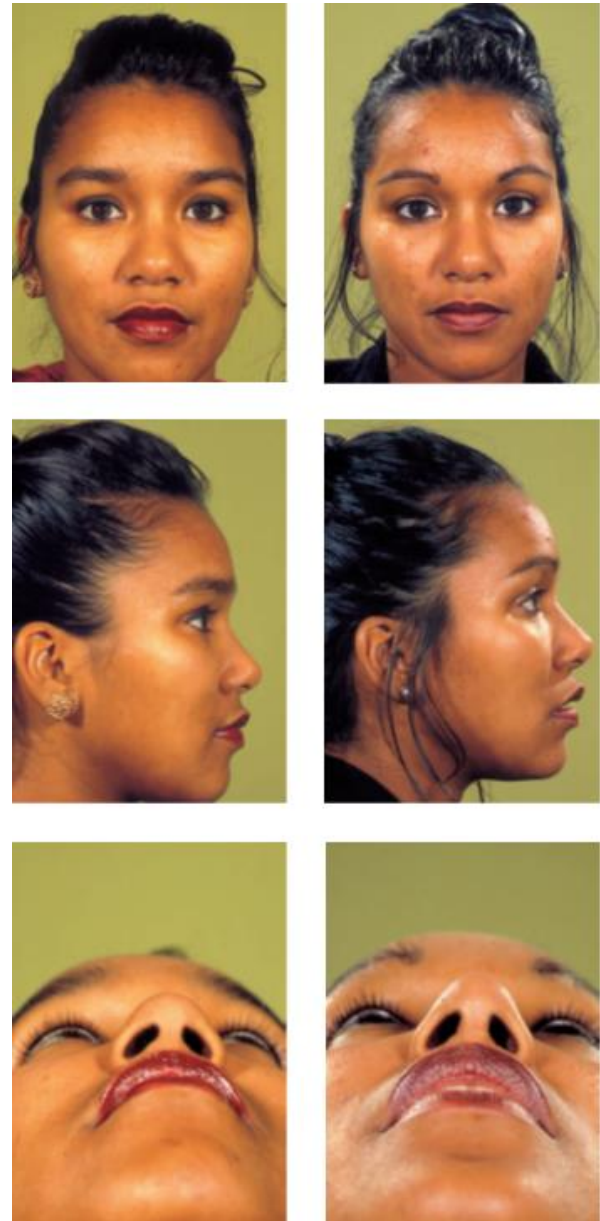

*Figure 16: Pre- (left) and postoperative (right) views of rhinoplasty by the **delivery approach**, to narrow the broad trapezoid tip with transdomal and interdomal suturing followed by a bilateral cephalic resection of the lower laterals and a small resection of the cartilaginous dorsum. The asymmetry of the nostrils due to a caudal septal deviation to the left was corrected by a septoplasty through a hemitransfixion incision*





*Figure 17: Pre- (left) and postoperative (right) views of a patient with a congenital deformity of the nose with agenesis of the nasal bones, overdevelopment of the cartilaginous vault and an extreme trapezoid deformity of the nasal tip. Narrowing of the tip with inter- and transdomal suturing and adequate cephalic tip rotation was performed with an interrupted strip technique through an external approach. Finally alar base wedge resections were performed to correct alar flaring*



*Figure 18: Pre- (left) and postoperative (right) views of a patient with a bulbous tip with lack of projection. An **external rhinoplasty** was performed for more tip projection and refinement with the use of autogenous grafts (columella strut and shield graft) from septal cartilage*

The material in this chapter originates from the textbook “**Rhinoplasty: A practical guide to functional and aesthetic surgery of the nose**” G.J. Nolst Trenité (ed) ISBN 978-90-6299-206-5 <https://www.rhinoplasty.nl/store/>

## Author

Gilbert Nolst Trenité MD, PhD  
Professor of Otorhinolaryngology  
Former President of European Academy of  
Plastic Surgery  
Amsterdam, Netherlands  
[nolsttrenite@gmail.com](mailto:nolsttrenite@gmail.com)

## Editor

Johan Fagan MBChB, FCS(ORL), MMed  
Professor and Chairman  
Division of Otolaryngology  
University of Cape Town  
Cape Town, South Africa  
[johannes.fagan@uct.ac.za](mailto:johannes.fagan@uct.ac.za)

***THE OPEN ACCESS ATLAS OF  
OTOLARYNGOLOGY, HEAD &  
NECK OPERATIVE SURGERY***

[www.entdev.uct.ac.za](http://www.entdev.uct.ac.za)



The Open Access Atlas of Otolaryngology, Head & Neck Operative Surgery by [Johan Fagan \(Editor\)](mailto:johannes.fagan@uct.ac.za) [johannes.fagan@uct.ac.za](mailto:johannes.fagan@uct.ac.za) is licensed under a [Creative Commons Attribution - Non-Commercial 3.0 Unported License](https://creativecommons.org/licenses/by-nc/3.0/)

